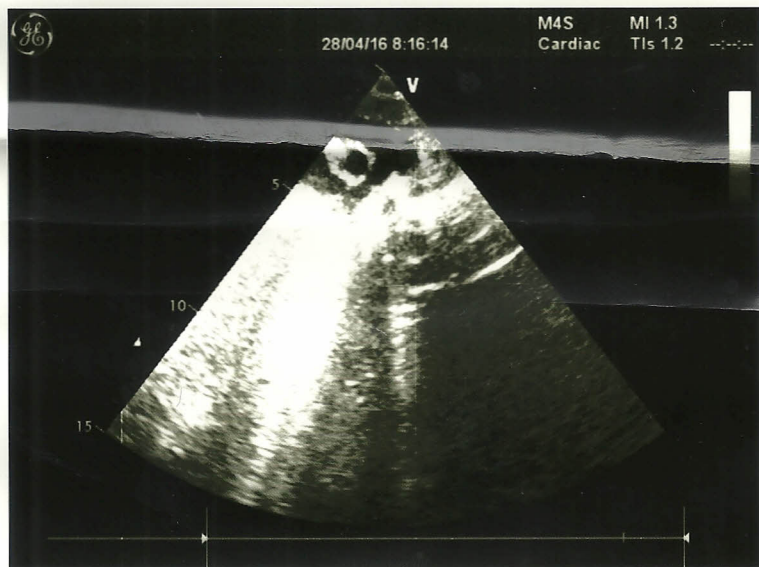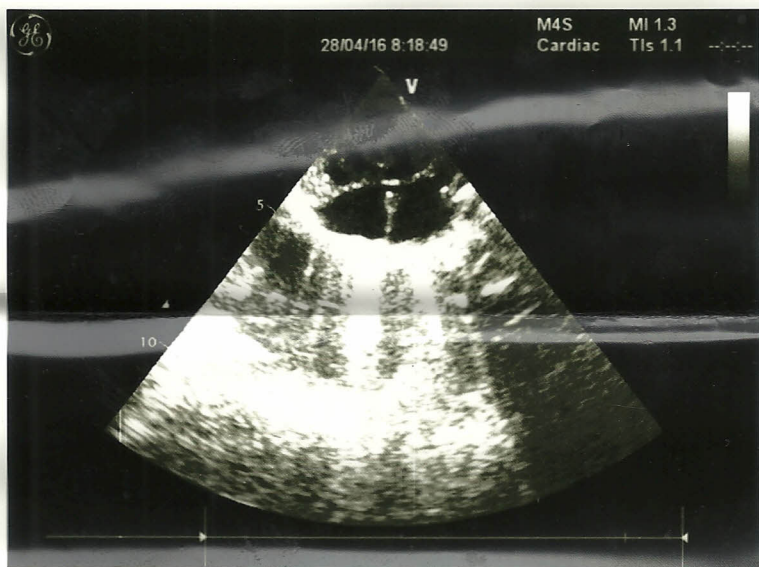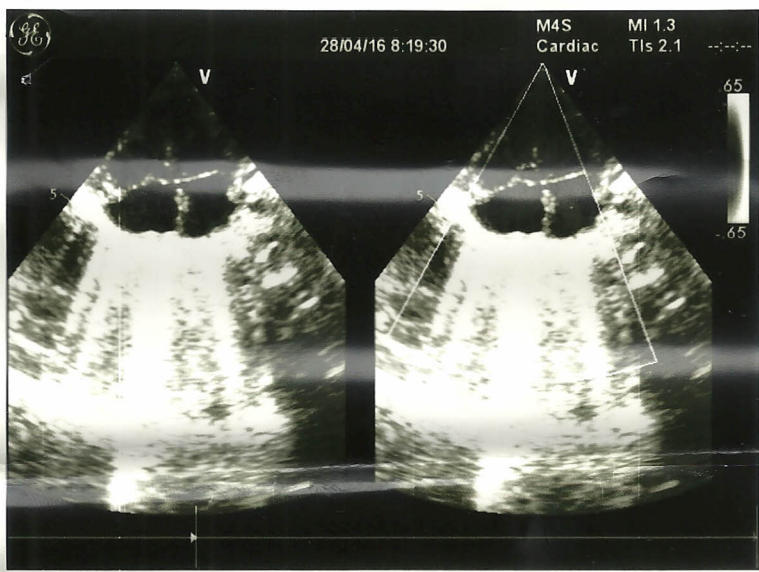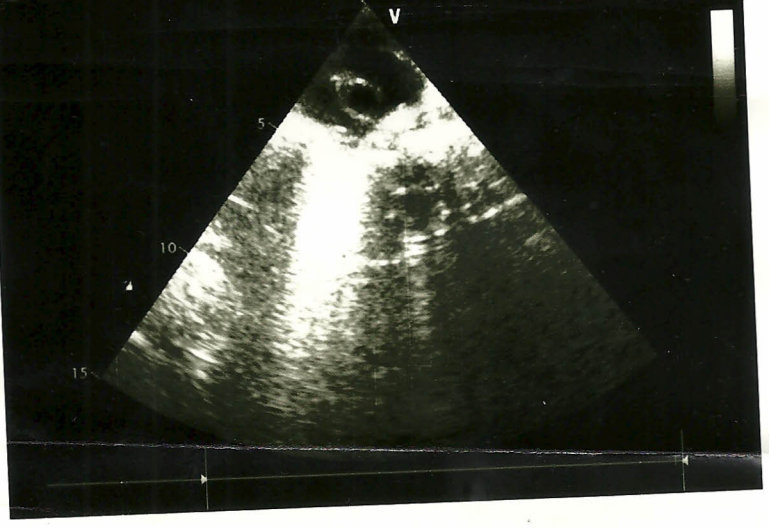


36

28/04/16 8:14:58

M4S  
Cardiac TIs 1.2





# St. Luke Cardiac Clinic

Loc: Ring road central,  
Hos. No 43 / Between Airtel  
& UBA Bank  
Tel: 026 4586910, 0303935865  
e-mail: info@stlcardiacclinic.com  
www.stlcardiacclinic.com

Date 28/04/16

## ECHOCARDIOGRAM REPORT

Name: Elaine Esther Owusu  
DOB: 10/04/16 Age: 2 weeks Sex: F Wt: 3.25 kg  
Indication for study: Pan Systolic Murmur

**Findings:** Situs solitus. AV and VA concordance. IVC and SVC to (Rt) atrium. Dilated (Rt) cardiac chambers; normal (Lb) cardiac chambers dimensions. MPA is dilated. Branched PAs are normal. No PDA. Normal biventricular systolic function.

There is an inlet VSD measuring 0.3 cm with (Lb) → (Rb) shunt across it.

There is a PFO measuring 0.3 cm with (Lb) → (Rb) shunt. There is an OP ASD measuring 0.3 cm with (Lb) → (Rb) shunt. There is a common AV junction

Measurement : (cm)	
Ao root:	<u>0.9</u>
Lt atrium:	<u>1.4</u>
RV:	<u>1.3</u>
RVAW:	<u>0.3</u>
LVEDD:	<u>1.9</u>
LVESD:	<u>1.0</u>
LVEF:	<u>81%</u>
FS:	<u>47%</u>
MPA:	<u>1.1</u>
RPA:	<u>0.7</u>
LPA:	<u>0.8</u>
ASD	<u>—————</u>
ASD -	<u>0.4 cm</u>
VSD -	<u>0.3 cm</u>

**Conclusion:**

**Recommendation:**

Dr. Gyan  
Cardiologist

→ P.T.O

but two separate AV valves. Normal AV and  
PV. Normal (L) sided aortic arch with no  
signs of coarctation.

Conclusion:

Partial AV canal with PFO  
and with signs of hemodynamic  
compromise.

Repeat echo in 2 months.

Dr. Gyan.

Version 2  
Study ID: 1875

## LITTLE HEARTS PAEDIATRIC CARDIAC SERVICES @ AKAI HOUSE CLINIC

<b>Name:</b> ELAINEOWUSU	<b>Study Date:</b> 03/09/2016 10:56
<b>Performed By:</b> N-A Y	<b>DOB:</b> 10/04/2016
<b>Referring Physician:</b> DR AKAMAH	<b>Age:</b> 4 mos
<b>Gender:</b> Female	<b>History:</b> ? Congenital Heart Disease
<b>Weight:</b> 6 kg	

### **Pediatric Echo**

BSA via weight only

### **Cardiac Position**

Levocardia. Abdominal situs solitus. Atrial situs solitus. D Ventricular Loop. S Normal position great vessels.

### **Veins**

Normal systemic venous drainage. Persistent left superior vena cava into coronary sinus. Normal pulmonary venous drainage.

### **Atrium**

Mild right atrial enlargement. Mild left atrial enlargement. Patent foramen ovale. Moderate atrial septal defect, primum type.

### **Atrioventricular Valves**

RIGHT ATRIO-VENTRICULAR VALVE.

Tricuspid valve deformities; unspecified.

LEFT ATRIO-VENTRICULAR VALVE.

Mitral valve deformities; unspecified. Common atrio-ventricular valve, Type A Rastelli.

### **Ventricles**

Dilated right ventricle, mild. Dilated left ventricle, mild. Moderate restrictive anterior muscular ventricular septal defect.

### **Semilunar Valves**

Normal pulmonic valve. Normal tricuspid aortic valve.

### **Great Vessels**

Small aorta.  
goose neck aorta.  
Normal pulmonary artery branches. No patent ductus arteriosus.

**Function**

Normal right ventricular systolic and diastolic function. Normal left ventricular systolic and diastolic function.

**Shunts**

Left to right atrial shunt, small. Left to right ventricular shunt, small. No patent ductus arteriosus detected.

---

**Interpretation Summary**

common atrioventricular junction.

Complete Atrioventricular Septal Defect with large atrial component and small ventricular component .

Moderate Left and right atrioventricular valve regurgitatuion.

**Comments**

initially seen at Trust Hospital and noted to have heart murmur.  
referred for echo done in the neonatal period-partial AV canal, parents understood infant had a PFO.

child was born at term with a BW 3kg no neonatal complications.

infant feeds well however sucks for short periods.

sits with support alert reacts to sound .

O/E.

well perfused, pink in room air. oxygen saturation in room air 97%, not tacypnoeic and no increased work of breathing, AHR 130.

S1, S2, normal 2-3/6PSM LLSE, no hepatomegaly, chest clinically clear.

**DIAGNOSIS & PLAN.**

CAVSD see details above.

thriving infant with no clinical compromise.

will need surgical repair around 6-9 months of age.

will need diuretics, review in 1 month to make clinical decesion.

see in 1 month.

Dr N-A Yao.

Consultant Paediatric & Congenital Cardiologist.